ZEBRAS OF MEDICINE:
WHEN THROMBOCYTES ARE SCARCE

THROMBOCYTOPENIA IN LIVER CIRRHOSIS VS IMMUNE THROMBOCYTOPENIC PURPURA

Natalie Ludwig[1]

[1] Master's student Molecular Mechanisms of Disease, Radboud university medical center, Nijmegen, The Netherlands

Abstract

Background: Thrombocytopenia describes abnormally low blood platelet counts in individuals. It is a common complication of numerous disorders and can be multifactorial in its cause. In liver cirrhosis, the origins of thrombocytopenia lie in a decreased liver function. Contrastingly, the low thrombocyte levels in immune thrombocytopenic purpura (ITP) are caused by autoantibodies targeting the blood platelets. A precise diagnosis of the patient is pivotal in order to select appropriate treatment.

Objective: This review aims to present the overlap and differences in symptoms between liver cirrhosis and ITP, raise awareness about the ambiguity between the two, and stress the importance of a proper diagnostic protocol.

Discussion: Thrombocytopenia is a key symptom in ITP, and up to 64% of cirrhotic liver patients present with abnormally low platelet counts. Furthermore, other cytopenias of leucocytes or erythrocytes tend to be absent in both conditions. In cirrhosis, the liver function is decreased, which becomes apparent following non-invasive diagnostic measures, such as imagining studies and biomarkers for liver function in the peripheral blood or following invasive measures like a liver biopsy. Regarding ITP, there are seldomly symptoms besides the abnormally low thrombocyte counts. The diagnosis is primarily a diagnosis of exclusion, making an unambiguous diagnosis more difficult. This diagnostic challenge stresses the importance of an in-depth investigation of the patient's health status. ITP can be distinguished in primary and secondary ITP, depending on whether the condition forms in response to a previous process or not (e.g. viral infection-induced or drug-induced). A clear distinction between the two conditions, ITP and liver cirrhosis, can substantially benefit the diagnostic process and improve the treatability of the condition.

Conclusion: In regard to liver cirrhosis and ITP, there is substantial overlap concerning symptoms. Furthermore, definite diagnostic measures for ITP are still lacking, making the process of diagnosing even more complicated. Nevertheless, a distinction between the two conditions is possible based on the patient's liver function and should be made in order to choose the appropriate form of treatment.

KEYWORDS: thrombocytopenia; autoimmunity; thrombopoietin; idiopathic thrombocytopenic purpura; platelets

Thrombocytopenia refers to a drastic abnormal lowering of blood platelet (i.e. thrombocyte) counts in the circulation [1]. The causes for this loss of thrombocytes are numerous and can be rooted in the production of thrombocytes, as well as their storage, functionality, and clearance [1]. This article aims to compare and delineate two causes for thrombocytopenia; liver cirrhosis being more common and immune thrombocytopenic purpura (ITP) being rarer.

Chronic liver diseases describe processes of continuous liver tissue destruction resulting in the replacement of healthy liver tissue by fibrous tissue, eventually leading to liver cirrhosis [2]. Globally, the number of liver cirrhosis cases increased by 74.53% between 1990 and 2017, with stark differences between countries [3]. Moreover, liver cirrhosis is ranked as the eleventh most common cause of death worldwide, causing approximately one million deaths in 2010 [2]. Common causes of this condition include hepatitis B and C, as well as alcohol abuse and non-alcoholic fatty liver disease [4]. Liver cirrhosis, more often than not, develops from an initial compensated form in which the liver can still carry out its necessary functions sufficiently, to a decompensated phase, where this is not the case anymore [4]. The classification of a patient into either the compensated or decompensated form is closely associated with his life expectancy, considering that median survival for a patient with compensated cirrhosis is considered to be over 12 years, whereas the median survival of patients with decompensated cirrhosis is merely approximately two years [5]. While the progression from compensated to uncompensated cirrhosis was traditionally thought to be an irreversible process, recompensation and even reversion of cirrhosis altogether have been described [4, 6].

Liver cirrhosis is strongly correlated with thrombocytopenia, as abnormally low platelet counts are found in as much as 64% of individuals diagnosed with liver cirrhosis, compared to 6% among non-cirrhotic patients with chronic liver disease [7]. The liver is crucial for the secretion of the hormone thrombopoietin, and, hence, the hormone levels are directly proportional to liver function [7, 8]. Thrombopoietin, in turn, induces differentiation into megakaryocytes (the progenitors of thrombocytes), while it also decreases platelet destruction through binding to matured thrombocytes [9, 10]. Thus, low levels of the hormone substantially impact thrombocyte levels, and loss of liver function indirectly reduces thrombocyte levels [10]. Furthermore, liver cirrhosis also directly augments platelet

destruction by a number of mechanisms, including heightened rates of platelet aggregation, immunologic destruction, and increased fibrinolysis [10]. Lastly, an increase in the blood pressure of the portal venous system (i.e. portal hypertension) induces thrombocytopenia via enlargement of the spleen (called splenomegaly) and, thereafter, an increased sequestering of thrombocytes in the spleen [11]. Thrombocytopenia is correlated with the long-term outcome of patients, which stresses the importance of proper treatment of thrombocytopenia for the cirrhotic patient [8, 12].

Different pathophysiological mechanisms are underlying ITP, which was previously also known as idiopathic thrombocytopenic purpura [10]. It has become evident that the pathophysiological processes are driven by autoreactive IgG antibodies targeting various platelet membrane proteins, like the glycoprotein VI [13, 14]. The binding of the autoantibody decreases the thrombocyte's half-life and interferes with thrombocyte production [14]. Nevertheless, the exact pathogenesis remains elusive and could also involve cytotoxic T cells attacking megakaryocytes in the bone marrow [14]. The autoantibodies can be drug- or illness-induced (thus, the associated ITP would be considered secondary ITP) or arise independently (then the ITP is categorised as primary ITP) [15].

Primary ITP can be further classified according to the duration of disease symptoms [15]. In the first three months following diagnosis, the disease is called newly diagnosed ITP. If the disease extends above this period for up to a year from the initial diagnosis, it is classified as persistent ITP. ITP persisting for more than 12 months from initial diagnosis is viewed as chronic ITP [15]. The epidemiology of ITP is thought to vary between age cohorts [16]. In 2009, the incidence of acute ITP (referring to incidences of ITP with durations of maximally 12 months) in children was investigated using previously published reports and estimated to be between 1.9 and 6.4 cases per 100,000 children [17]. In the same study, the incidence of ITP among adults was assessed and estimated to be between 1.6 and 3.9 cases per 100,000 individuals [17]. However, the underlying data are mostly derived from European countries, and, therefore, these results could be subject to geographical bias [17]. Most children only develop a newly diagnosed ITP and spontaneously recover again after three months, while adults tend to develop a chronic form of ITP [18]. Interestingly, sex disproportions among the patients vary too, according to the age of the investigated cohort [16].

While liver cirrhosis and ITP are very different in their pathogenesis, their overlap in causing thrombocytopenia and splenomegaly could cause confusion while diagnosing a patient presenting with low thrombocyte counts. However, up to now, no direct comparison between these two disorders has been drawn. This review aims to compare the clinical presentation, diagnosis, and treatment between both conditions in order to outline the common aspects, as well as the differences between the disorders. Furthermore, awareness should be raised that while ITP is much rarer than liver cirrhosis, it is still an important cause of thrombocytopenia and must, therefore, not be forgotten.

Clinical presentation

Patients suffering from liver cirrhosis often show little to no symptoms early on but will develop a number of symptoms at later disease stages. Early symptoms can include nausea, poor appetite, and mild abdominal discomfort, while later symptoms are more severe, such as jaundice and the collection of body fluids in the abdomen (i.e. ascites) and lower part of the legs and feet (i.e. oedema) [19]. Among cirrhotic patients, both hypersplenism (an overactive spleen) and splenomegaly are common complications [7]. These conditions, in combination with a progressively worse liver function, can lead to thrombocytopenia in the patient, and thus more frequent bleeding events [7, 19]. Histologically, cirrhosis presents as advanced liver fibrosis, distorting the surrounding liver vasculature [20]. Fibrosis describes the process of replacing damaged functional tissue with fibrous scar tissue, ultimately leading to loss of function of the organ if the fibrosis becomes excessive [20]. In the liver, occurring fibrosis increases the distance between hepatocytes and the nearest blood vessel, effectively cutting off hepatocytic islands from the blood supply [20].

Patients suffering from ITP, on the other hand, are generally well-appearing and present with only a few symptoms throughout the disease [16]. The strongest indicator is the thrombocytopenia itself, with a thrombocyte count of below 100,000/µl blood [16]. The counts of white blood cells, however, are in the normal range, as is the amount of haemoglobin, making the thrombocytopenia isolated [16]. Furthermore, patients show a generalised purpuric rash and may present with splenomegaly [16, 21]. However, the clinically most relevant symptom is bleeding of varying degrees, as it is a central cause of both morbidity and mortality [22, 23]. Strikingly, severe bleeding in the form of intracerebral haemorrhage occurs more in adults than children (1.4% vs 0.4%), while other forms of severe bleeding are more common in children than adults (20.2% vs 9.6%) [22]. Severe bleeding was associated with platelet counts below 20,000 platelets/µl blood, previous minor bleeding, and old age [22, 24].

Diagnosis

The diagnosis of liver cirrhosis is a multi-step process (Figure 1). Up until recently, liver biopsies were universally considered the gold standard of diagnosis of liver cirrhosis [4, 11, 25]. This procedure, however, is highly invasive and painful, shows an error rate of as much as 20%, and is not well suited for serial applications to determine disease progression [26-28]. Thus, other, less invasive diagnostic methods are currently under development [11]. Liver function (inversely correlated with liver cirrhosis) can also be determined non-invasively using biomarkers, such as serum albumin, cholesterol, cholinesterase, and coagulation factors [29].

Other approaches to the non-invasive diagnosis of liver cirrhosis are imaging methods, such as sonography, CT scans, and MRI scans [4]. In the past decade, sonography gained further importance due to the development of new applications like liver stiffness measurement and transient elastography (FibroScan) [4, 28]. Briefly, vibrations with a frequency of 50 Hz and mild amplitudes provoke a wave of shear stress that travels through the tissue. The velocity of the wave is measured and translates directly to the elasticity of the tissue [28]. Recently, it has been argued that transient elastography has the potential to eventually replace tissue biopsies as gold standards of diagnosis due to its non-invasive nature, low costs, and fast procedure, allowing for serial applications [25]. Furthermore, the procedure shows high accuracy in detecting advanced fibrosis of the liver, defined as stage F3 and above in a fibrosis classification system of F0 (no fibrosis) to F4 (cirrhosis) [30]. Advanced fibrosis is associated with an increased risk of worse clinical outcomes [31]. It needs to be noted, however, that this form of detection is negatively impacted by obesity, and the patient groups of the performed studies all showed a mean body mass index of maximally 30; thus, this diagnostic measure could potentially not be available for all patients [30].

After determining the presence of cirrhosis, the stage of compensation has to be determined next in a thorough examination of the patient [4]. In case of the presence of any potentially life-threatening complications such as ascites, sepsis, hepatic encephalopathy (brain

damage due to a reduced liver function and a subsequent build-up of toxins in the circulation), or thrombocytopenia, the cirrhosis is considered to be decompensated, and respective steps to treat the condition are taken [4, 11, 32].

ITP, on the other hand, is diagnosed primarily by exclusion criteria, following the observation of a platelet count of under 100,000 platelets/µl blood [16]. This lowered threshold (compared to the threshold of 150,000 thrombocytes/µl blood) is due to the fact that some individuals display low thrombocyte counts (between 100,000 and 150,000 platelets/µl blood) despite appearing healthy otherwise [15]. Laboratory evaluation should be performed to decide whether the thrombocytopenia is isolated, including differential laboratory evaluation, reticulocyte count, peripheral blood smear, blood type, and direct antiglobulin test. [33].

A crucial step in the diagnosis of ITP is deciding between primary and secondary ITP [16]. To this end, the history of the patient with respect to recent viral infections and received vaccinations should be clarified [34-37]. In light of the current pandemic of the SARS-CoV-2, it is interesting to note that secondary ITP was described as a complication following infection with SARS-CoV-2 in at least 45 cases up until September 2020 [38]. During the process of diagnosis, other causes of secondary ITP should be investigated as well, including drugs associated with thrombocytopenia, as well as related symptoms like weight loss, fever, or previous bleeding episodes of the patient [16].

Treatment

There are numerous approaches to treating liver cirrhosis, depending on the stage and severity of the condition and the presence of complications, which is why this article focusses on treating thrombocytopenia in cirrhotic patients [4]. A definite cure to chronic liver diseases, such as liver cirrhosis, are liver transplantations. However, while the cure rate nowadays is up to 80% in patients five years after transplantation, the waiting list can be extensive, and the costs are substantial [11, 39-41]. Thus, other treatment options should be considered [39, 40]. Another approach is a transjugular intrahepatic portosystemic shunt, which functions as a connection between the portal and hepatic vein, thereby relieving portal hypertension [42]. The procedure convinces with its low invasiveness and effectiveness against portal hypertension. Nevertheless, several severe complications (e.g. cardiac decompensation) make this procedure not suitable for all patients [43].

Up until today, it remains highly debated whether an increase in thrombocyte levels actually benefits the patient or whether the consequences of the procedure outweigh the health advantages [40]. On the one hand, platelet levels can be increased indirectly by targeting the spleen. Splenectomy, referring to the removal of the spleen, either in open surgery or laparoscopically via a small opening of the abdomen and a camera, remains controversial due to the bleeding risk in thrombocytopenic patients during surgery and the substantial morbidity of patients [44, 45]. Another approach is the partial splenic arterial embolisation, which is performed on cirrhotic patients presenting with splenomegaly and thrombocytopenia. In this treatment, the blood supply to small stretches of the spleen is impeded, resulting in their necrosis and, thus, a decrease in spleen size [46, 47]. The risk of complications rises with an increase in embolised spleen mass and includes pneumonia, peritonitis, and portal vein thrombosis [48]. The technique achieves results comparable to laparoscopic splenectomy but is associated with fewer risks [48].

Platelet levels can also be increased directly, either by platelet transfusions or administration of thrombopoietin receptor agonists.

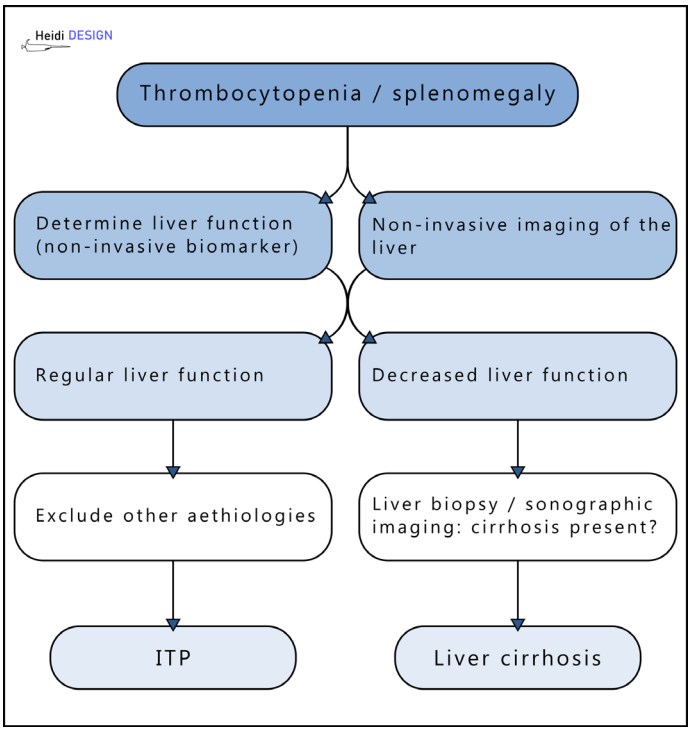

Figure 1: Flowchart of the differential diagnosis between liver cirrhosis and ITP.

Liver cirrhosis and ITP can both cause thrombocytopenia, as well as splenomegaly (an increase in spleen size). To distinguish these two conditions, the liver function must be determined using both non-invasive markers and imaging techniques, such as MRI. If the liver function is normal, ITP can be diagnosed by excluding all other possible conditions. If the liver function is decreased, the presence and extent of fibrosis can be determined using non-invasive sonographic imaging or invasive liver biopsies. ITP: immune thrombocytopenic purpura

Platelet transfusion improved liver regeneration in several *in vivo* studies using mice or rats, which is why its therapeutic potential for cirrhotic patients suffering from chronic liver disease-induced thrombocytopenia was investigated [40, 49, 50]. These patients were treated with platelet transfusions for 12 weeks, and both platelet counts, as well as liver function, were assessed in each patient [40]. The blood thrombocyte levels did not increase; nevertheless, the liver function increased markedly [51]. Values for serum albumin, serum cholinesterase, and serum hyaluronic acid showed a constant trend towards improvement, despite not being significant [51]. This increment could indicate a potential positive effect of platelet transfusions in liver cirrhosis [51]. However, the trial was non-controlled, non-randomised, and consisted of only a small patient cohort (six patients), and thus needs to be repeated in an improved study design including more patients to determine the clinical significance [40, 51]. Of note, platelet transfusions can cause serious side-effects, such as portal vein thrombosis and febrile reactions ranging from sole increases in body temperature to rigour and respiratory distress [40, 52, 53].

Hence, other methods have been explored to raise thrombocyte levels, including administration of thrombopoietin receptor agonists (e.g. eltrombopag, lusutrombopag, avatrombopag) [40]. Two agonists, lusutrombopag and avatrombopag, are currently approved by the US Food and Drug Administration for use in treating thrombocytopenia in adult patients with chronic liver diseases prior to them undergoing a surgical procedure [44]. A third drug, eltrombopag, has also undergone clinical trials but has not gained approval after

the observation was made that thrombotic events of the portal venous system were significantly increased in the treatment group over the control group (odds ratio of eltrombopag 3.04; 95% confidence interval 0.62-14.82) [52]. This discovery highlights the need for further research on eltrombopag and similar drugs and their association with thrombosis development in terms of determination of risk factors and dose optimisation. Until then, eltrombopag cannot be recommended as an alternative to platelet transfusion [52].

Treatments for ITP, on the other hand, can be classified into first-line and second-line treatments, the latter of which are administered if first-line treatment fails [16]. Generally, all patients should avoid antiplatelet therapies. Furthermore, patients with a platelet count of less than 20,000 platelets/µl blood should additionally stay clear off anti-coagulant therapies, and children with a platelet count of less than 30,000 platelets/µl blood especially should be discouraged from contact and collision sports and other activities associated with an increased risk of bleeding [16]. Generally, patients need to be monitored with respect to bleeding and their platelet counts [16]. About 50-70% of children recover spontaneously from ITP without the need for treatment [33].

First-line treatments primarily consist of the administration of glucocorticoids, namely prednisolone for children and prednisolone or dexamethasone for adults [33]. Children who cannot receive prednisolone can also be treated with either intravenous immunoglobulin or anti-D immunoglobulin [33]. If these first-line treatments fail or the ITP develops into a chronic form, second-line treatments can be administered [16]. For children, second-line treatments mainly consist of therapy with thrombopoietin receptor agonists, or if this fails, treatment with rituximab, an antibody that induces depletion of B cells [33, 54]. For adult patients, second-line treatments consist of thrombopoietin receptor agonists, rituximab, and finally, splenectomy [33].

Conclusions

Thrombocytopenia is a complex pathology and can have numerous origins. Thus, determining the exact cause of the thrombocytopenia is crucial for the most suitable and correct treatment. Thrombocytopenia as a consequence of liver cirrhosis has its cause in the liver and primarily in the reduction of thrombopoietin levels, while thrombocytopenia stemming from ITP is caused by autoantibodies targeting the blood platelets.

The two causes can be distinguished by determining the liver function and stiffness using biomarkers, non-invasive imaging techniques, or invasive liver biopsies, thereby determining whether the liver could be the origin of the low thrombocyte levels. This finding has imminent implications for the patient's treatment. The benefit of platelet transfusions to increase thrombocyte levels in cirrhotic patients is still debated among scientists, while increasing platelet levels in prolonged ITP is much more accepted. Thus, by utilising the outlined diagnostic measures, doctors can determine the origin of the thrombocytopenia and use this knowledge to provide the patient with the most befitting treatment.

Acknowledgements

RAMS would like to thank Prof. Joost Drenth, Department of Gastroenterology and Hepatology, Radboudumc, Nijmegen, The Netherlands and Arno Stellingwerf, BSc, for providing the author of this article with feedback.

References

1. National Heart, Lung, and Blood Institute; National Institutes of Health; U.S. Department of Health and Human Services. Thrombocytopenia. 27 December 2021. https://www.nhlbi.nih.gov/health-topics/thrombocytopenia.
2. Asrani, S.K., *et al.* Burden of liver diseases in the world. *J Hepatol* **70**, 151-171 (2019).
3. Zhai, M., *et al.* The burden of liver cirrhosis and underlying etiologies: results from the global burden of disease study 2017. *Aging* **13**, 279 - 300 (2021).
4. Xu, X.Y., *et al.* Chinese guidelines on the management of liver cirrhosis (abbreviated version). *World J Gastroenterol* **26**, 7088-7103 (2020).
5. D'amico, G., *et al.* Natural history and prognostic indicators of survival in cirrhosis: a systematic review of 118 studies. *J Hepatol* **44**, 217-231 (2006).
6. Lo, R.C. & Kim, H. Histopathological evaluation of liver fibrosis and cirrhosis regression. *Clin Mol Hepatol* **23**, 302-307 (2017).
7. Bashour, F.N., *et al.* Prevalence of Peripheral Blood Cytopenias (Hypersplenism) in Patients With Nonalcoholic Chronic Liver Disease. *The American Journal of Gastroenterology* **95**, 2936-2939 (2000).
8. Giannini & E. Relationship between thrombopoietin serum levels and liver function in patients with chronic liver disease related to hepatitis C virus infection. *The American Journal of Gastroenterology* **98**, 2516-2520 (2003).
9. De Sauvage, F.J., *et al.* Stimulation of megakaryocytopoiesis and thrombopoiesis by the c-Mpl ligand. *NATURE* **369**, 533-538 (1994).
10. Mitchell, O., *et al.* The pathophysiology of thrombocytopenia in chronic liver disease. *Hepat Med* **8**, 39-50 (2016).
11. Sigal, S.H., *et al.* Clinical Implications of Thrombocytopenia for the Cirrhotic Patient. *Hepat Med* **12**, 49-60 (2020).
12. Lu, S.N., *et al.* Thrombocytopenia as a surrogate for cirrhosis and a marker for the identification of patients at high-risk for hepatocellular carcinoma. *Cancer* **107**, 2212-2222 (2006).
13. Boylan, B., *et al.* Anti-GPVI-associated ITP: an acquired platelet disorder caused by autoantibody-mediated clearance of the GPVI/FcRgamma-chain complex from the human platelet surface. *Blood* **104**, 1350-1355 (2004).
14. Zufferey, A., *et al.* Pathogenesis and Therapeutic Mechanisms in Immune Thrombocytopenia (ITP). *J Clin Med* **6**, 1-21 (2017).
15. Rodeghiero, F., *et al.* Standardisation of terminology, definitions and outcome criteria in immune thrombocytopenic purpura of adults and children: report from an international working group. *Blood* **113**, 2386-2393 (2009).
16. Pietras, N.M. & Pearson-Shaver, A.L. Immune Thrombocytopenic Purpura. in StatPearls [Internet], Treasure Island (FL): StatPearls Publishing, 24 September 2020.
17. Terrell, D.R., *et al.* The incidence of immune thrombocytopenic purpura in children and adults: A critical review of published reports. *Am J Hematol* **85**, 174-180 (2010).
18. J Justiz Vaillant, A.A. & Gupta, N. ITP-Immune Thrombocytopenic Purpura. in StatPearls [Internet], Treasure Island (FL): StatPearls Publishing, 15 December 2020.
19. National Institute of Diabetes and Digestive and Kidney Diseases; National Institutes of Health; U.S. Department of Health and Human Services. Cirrhosis. 30 January 2021. https://www.niddk.nih.gov/health-information/liver-disease/cirrhosis?dkrd=hispt0382.
20. Schuppan, D. & Afdhal, N.H. Liver cirrhosis. *Lancet* **371**, 838–851 (2006).
21. Hassan, A., *et al.* Clinical feature and management of immune thrombocytopenic purpura in a tertiary hospital in Northwest Nigeria. *Niger Med J.* **58**, 68–71 (2017).

22. Neunert, C., *et al.* Severe bleeding events in adults and children with primary immune thrombocytopenia: a systematic review. *J Thromb Haemost* **13**, 457-464 (2015).
23. Portielje, J.E.A., *et al.* Morbidity and mortality in adults with idiopathic thrombocytopenic purpura. *Blood* **97**, 2549-2554 (2001).
24. Cohen, Y.C., *et al.* The Bleeding Risk and Natural History of Idiopathic Thrombocytopenic Purpura in Patients With Persistent Low Platelet Counts. *Archives of Internal Medicine* **160**, 1630-1638 (2000).
25. Mumtaz, S., *et al.* Pro Noninvasive Imaging Has Replaced Biopsy as the Gold Standard in the Evaluation of Nonalcoholic Fatty Liver Disease. *Clinical liver Disease* **13**, 111-113 (2019).
26. Cadranel, J.F., *et al.* Practices of Liver Biopsy in France: Results of a Prospective Nationwide Survey. *Hepatology* **32**, 477-481 (2000).
27. Afdhal, N.H. Diagnosing fibrosis in hepatitis C: is the pendulum swinging from biopsy to blood tests?. *Hepatology* **37**, 972-974 (2003).
28. Castera, L., *et al.* Non-invasive evaluation of liver fibrosis using transient elastography. *J Hepatol* **48**, 835-847 (2008).
29. Abbas, M. & Abbas, Z. Serum cholinesterase: A predictive biomarker of hepatic reserves in chronic hepatitis D. *World J Hepatol* **9**, 967-972 (2017).
30. Musso, G., *et al.* Meta-analysis: natural history of non-alcoholic fatty liver disease (NAFLD) and diagnostic accuracy of non-invasive tests for liver disease severity. *Ann Med* **43**, 617-649 (2011).
31. Taylor, R.S., *et al.* Association Between Fibrosis Stage and Outcomes of Patients With Nonalcoholic Fatty Liver Disease: A Systematic Review and Meta-Analysis. *Gastroenterology* **158**, 1611-1625 (2020).
32. Deng, H., *et al.* Diagnostic Accuracy of APRI, AAR, FIB-4, FI, King, Lok, Forns, and FibroIndex Scores in Predicting the Presence of Esophageal Varices in Liver Cirrhosis: A Systematic Review and Meta-Analysis. *Medicine (Baltimore)* **94**, e1795 (2015).
33. Neunert, C., *et al.* American Society of Hematology 2019 guidelines for immune thrombocytopenia. *Blood Adv* **3**, 3829-3866 (2019).
34. Liebman, H.A. Viral-Associated Immune Thrombocytopenic. *Hematology* **1**, 212-218 (2008).
35. O'leary, S.T., *et al.* The risk of immune thrombocytopenic purpura after vaccination in children and adolescents. *Pediatrics* **129**, 248-255 (2012).
36. Hamiel, U., *et al.* Recurrent Immune Thrombocytopenia After Influenza Vaccination: A Case Report. *Pediatrics* **138**, e20160124 (2016).
37. Kumar, S., *et al.* Immune thrombocytopenic purpura due to mixed viral infections. *Indian J Pediatr* **80**, 421-422 (2013).
38. Bhattacharjee, S. & Banerjee, M. Immune Thrombocytopenia Secondary to COVID-19: a Systematic Review. *SN Compr Clin Med*, 1-11 (2020).
39. Samuel, D. & Coilly, A. Management of patients with liver diseases on the waiting list for transplantation: a major impact to the success of liver transplantation. *BMC Med* **16**, 1-5 (2018).
40. Kurokawa, T. & Ohkohchi, N. Platelets in liver disease, cancer and regeneration. *World J Gastroenterol* **23**, 3228-3239 (2017).
41. Taylor, M.C., *et al.* Factors associated with the high cost of liver transplantation in adults. *Can J Surg* **45**, 425-434 (2002).
42. Rössle, M., *et al.* NEW NON-OPERATIVE TREATMENT FOR VARICEAL HAEMORRHAGE. *The Lancet* **334**, 153 (1989).
43. Garcia-Pagan, J.C., *et al.* Where does TIPS fit in the management of patients with cirrhosis? *JHEP Rep* **2**, 100122 (2020).
44. Saab, S. & Brown, R.S., Jr. Management of Thrombocytopenia in Patients with Chronic Liver Disease. *Dig Dis Sci* **64**, 2757-2768 (2019).
45. Giannini, E.G., *et al.* Incidence of bleeding following invasive procedures in patients with thrombocytopenia and advanced liver disease. *Clin Gastroenterol Hepatol* **8**, 899-902 (2010).
46. Nagata, J., *et al.* Vaginal bleeding in a patient with type C liver cirrhosis without a past history of laparotomy: successful treatment with partial splenic artery embolisation. *Clin J Gastroenterol* **5**, 275-281 (2012).
47. Maddison, F.E. Embolic Therapy of Hypersplenism. *Investigative Radiology* **8**, 280-281 (1973).
48. Gangireddy, V., *et al.* Management of thrombocytopenia in advanced liver disease. *Can J Gastroenterol Hepatol 2014* **28**, 558-564 (2014).
49. Matsuo, R., *et al.* Platelet administration via the portal vein promotes liver regeneration in rats after 70% hepatectomy. *Ann Surg* **253**, 759-763 (2011).
50. Liu, G., *et al.* Splenectomy after partial hepatectomy accelerates liver regeneration in mice by promoting tight junction formation via polarity protein Par 3-aPKC. *Life Sci* **192**, 91-98 (2018).
51. Maruyama, T., *et al.* Platelet transfusion improves liver function in patients with chronic liver disease and cirrhosis. *Tohoku J Exp Med* **229**, 213-220 (2013).
52. Afdhal, N.H., *et al.* Eltrombopag before procedures in patients with cirrhosis and thrombocytopenia. *N Engl J Med* **367**, 716-724 (2012).
53. Chambers, L.A., *et al.* Febrile reactions after platelet transfusion: the effect of single versus multiple donors. *TRANSFUSION* **30**, 219-221 (1990).
54. Terrell, D.R., *et al.* Immune Thrombocytopenia (ITP): Current Limitations in Patient Management. *Medicina (Kaunas)* **56**, 1-10 (2020).