CERVICAL CANCER: DIAGNOSTIC ACCURACY OF NANO-MRI

Daniëlle J. van Dis[1], Janoe J.A.W. van Hemert[1], Vera E. Mekers[1], Renee M.W. Smets[1], Maaike ten Westenend[1]

Corresponding Author: Janoe J.A.W. van Hemert (janoevanhemert@hotmail.nl)

[1]Bachelor Biomedical Science student, Department of Health Evidence, Radboud University Medical Center, Nijmegen, the Netherlands

ABSTRACT

Systematic Review

BACKGROUND: The current technique (PET/CT) to detect lymphatic metastases in cervical cancer does not have the desired accuracy. This means not all patients with lymphatic metastases are correctly diagnosed. A lack in accuracy leads to unnecessary false negatives and false positives. Therefore a new technique is needed, nano-MRI can be the solution.
OBJECTIVE: Study sensitivity and specificity of nano-MRI compared to PET/CT in the diagnosis of pelvic lymph node metastases in women with cervical carcinoma.
METHODS: PubMed and Embase were searched to find relevant articles. After selection based on title and abstract, 23 articles were included. A study was selected when the following criteria were met: domain, determinant and outcome were present; sensitivity and specificity were calculated. Articles were evaluated for the critical appraisal using the QUADAS-2 tool and the relevant data was extracted and pooled.
RESULTS: The overall sensitivity and specificity of PET/CT including all the studies were 56% (95% CI: 50%-63%) and 60% (95% CI: 56%-64%), respectively. The overall sensitivity and specificity for nano-MRI including all of the studies were 83% (95% CI: 78%-87%) and 87% (95% CI: 84%-89%), respectively.
CONCLUSION: Nano-MRI is expected to be a better alternative to detect metastases in pelvic lymph nodes in women with cervical cancer in comparison to PET/CT. But no solid conclusion can be drawn and therefore further research is needed.

WHAT'S KNOWN: To date, detecting lymphatic metastasis in cervical cancer is done with PET/CT, but this lacks accuracy. A low accuracy causes unwanted errors in lymph node metastases diagnostics.

WHAT'S NEW: According to our results, the specificity of PET/CT is 56% (95% CI: 50%-63%) compared to 83% (95% CI: 78%-87%) of nano-MRI. The sensitivity of PET/CT is 60% (95% CI: 56%-64%) compared to 87% (95% CI: 84%-89%) of nano-MRI. This indicates that nano-MRI would be a better alternative to detect metastases in lymph nodes in women with cervical cancer than PET/CT.

KEYWORDS: Nano-MRI, PET/CT scan, Cervical Cancer, Pelvic Lymphatic Metastasis, Sensitivity and Specificity

*Supplementary material has been marked with * and can be found online at www.ramsresearch.nl*

Introduction

Cervical cancer is a type of cancer arising from the cervix. It can develop after infection of cervix cells with human papilloma virus (HPV), which causes changes in the transition area from columnar epithelium to squamous epithelium. These changes in the transition area can lead to the precursor stage of cervical cancer [1, 2]. When a gynecologist diagnoses cervical cancer, the stage of the tumor is determined by FIGO guidelines [3, 4]. FIGO guidelines score according to size and invasiveness of the tumor. There are four main stages, which are divided into two overall stages namely the early and late stage. In an early stage the tumor is relatively small and has not grown into surrounding tissues. This in contrast to the late stage tumors, which are relatively large and have grown into surrounding tissues [4]. The risk of metastases is higher in a late stage (20%-92%), but the risk in an early stage cannot be ignored (<20%)[1].Treatment of tumors in early stages consists of surgically removing the uterus and all the pelvic lymph nodes [5]. Late stage tumors are mainly treated with radiotherapy because these tumors cause too many complications and difficulties when surgically removed. These difficulties include cells getting loose which can result in metastases, when the uterus is surgically removed. Removing the whole tumor will cause even more difficulties because it is inevitable to surgically remove the tumor without damaging the surrounding tissues. This can lead to major complications, e.g peritonitis.

Cervical cancer metastasizes mainly through lymphatic vessels. The pelvic nodes are in 98 to 100% of the cases affected first. It is important to detect possible metastases, because these patients should be treated with chemotherapy in addition to their usual intervention to improve their prognosis [6]. To determine metastases in early stages, removed lymph nodes are histological evaluated. In case of a late stage tumor there is no surgical intervention and metastases are detected with a PET/CT scan. Recent studies show a low accuracy of the PET/CT [6-15]. This means that not all patients with metastases are found with this diagnostic tool or patients are over treated [9, 10, 15]. False negatives, which include patients with metastases that are not found and so do not get treatment against these metastases, have major implications for the prognosis of these patients [16]. The false negatives in the diagnosis of lymph node metastases in women with cervical carcinoma are usually the cause of an adverse prognosis.

For this reason we studied PET/CT in comparison to a new method to detect metastases namely nano-MRI. With this procedure a contrast agent called ferumoxtran-10 (which is an ultra-small particle of iron oxide, also called USPIO) is injected intravenously. After approximately 24 hours, the iron particles have had enough time to spread through the whole body. They have been taken up by macrophages and these transport the iron oxide particles to the lymph nodes. In normal lymph nodes, iron loaded macrophages can spread through the whole node. However, if the lymph node contains metastases, this is not possible. Iron particles are

less present in metastases in comparison to normal lymph node tissue, because macrophages cannot penetrate the tumorous tissue. A low signal will be detected when many iron particles are present in the lymph node. A low signal correlates to no present metastases. A high signal means there are a low amount of iron particles present, which suggests there is a metastasis in the lymph node [17].

In men with prostate cancer, research proved that nano-MRI can detect metastases at 2 mm, while PET/CT detects metastases at a minimal of 8 mm according to Radboud University Medical Center [18]. Because metastases are found earlier with the use of nano-MRI, more effective and personalized treatment can be given, such as chemotherapy, pelvic lymph node dissection or radiotherapy. The use of USPIO for the diagnosis of lymphatic metastases in prostate cancer can also be applied for the diagnosis of lymphatic metastases in cervical cancer. This means fewer side effects for the patient and a greater chance to cure from cervical cancer. This is why this study focuses on the sensitivity and specificity of nano-MRI compared to PET/ CT to diagnose pelvic lymph node metastases in women with cervical carcinoma [12], writing a systematic literature review. The review will focus on the following question: what is the accuracy of nano-MRI in comparison to PET/CT in detecting lymph node metastases in women with cervix carcinoma?

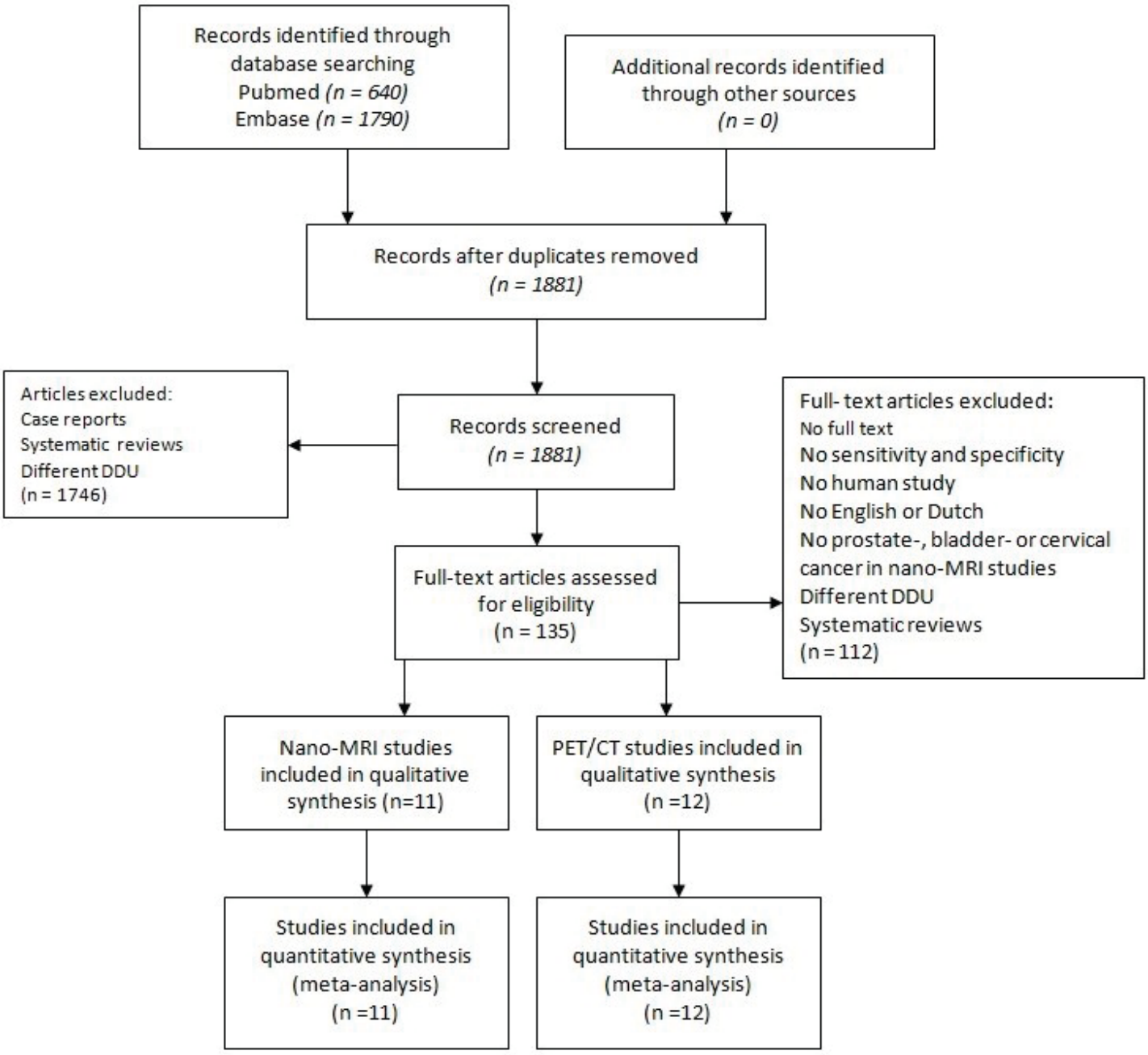

Figure 1: *Flow chart of the research strategy. We retrieved the first selection of articles in PubMed and Embase with the search strategy shown in table 1*. A study was selected when the following criteria were met: domain, determinant and outcome were present; sensitivity and specificity were calculated.*

Methods

Search and selection
Firstly, we formulated a diagnostic research question on the predictive value of nano-MRI in comparison to PET/CT, which is stated in the introduction. Due to the fact that little research has been done on the comparison between nano-MRI and PET/CT in women with cervical cancer we decided to divide our clinical question into two separate questions.

The first sub-question states: what is the accuracy of nano-MRI in the diagnosis of lymph node metastases in women with cervix carcinoma? And the second sub-question states: what is the accuracy of PET/CT in the diagnosis of lymph node metastases in women with cervix carcinoma?

A search filter was designed for both of the sub-questions separately by using relevant synonyms for the domain, cervical cancer and other types of cancers for nano-MRI, determinant, nano-MRI or PET/CT, and for the outcome, pelvic lymph node metastases (Table 1*).

By using title and abstract terms, MeSH and EMTREE terms in the search strategy we found relevant publications in Embase and PubMed. The titles and abstracts of all of these articles were screened for selection. For a more in depth selection the full-text of eligible studies were screened. A study was selected when the following criteria were met: domain, determinant and outcome were present; sensitivity and specificity were calculated or could be calculated using the true positives, true negatives, false positives and false negatives.

Systematic reviews, congress abstracts, animal studies, studies with no full text available and studies with languages other than Dutch or English were excluded.

The search yielded 640 articles in PubMed and 1790 articles in Embase (Figure 1). In total 1881 unique studies were retrieved. Screening the titles and abstracts and the full-text of the remaining studies resulted in 112 articles being excluded. So in conclusion 23 articles were adequate.

Critical appraisal
The quality of methods and reporting of results of the remaining 23 articles were critically appraised according to the criteria in the QUADAS guideline [19] and are presented in Table 2. Articles which scored 2 times high at risk of bias for nano-MRI and 3 times high at risk of bias for PET/CT were seen as low quality. The reason for this is that studies regarding PET/CT are more frequently done and therefore were more critically looked upon.

Statistical analysis
Sensitivity and specificity were used as the principal summary measures. The sensitivity and specificity data were extracted from the articles. The true positives, true negatives, false positives and false negatives were calculated by hand or extracted from the article, if possible. This data was analyzed with a program called Review Manager (RevMan). RevMan provides analytic methods to summarize your results in for example a forest plot. Since a pooled estimator is not possible in RevMan for a diagnostic study, the studies were combined into one overall study and sensitivity and specificity were calculated by RevMan for PET/CT and nano-MRI separately.

The final analysis of the results were executed both with and without the articles which scored high at risk of bias according to the critical appraisal to see if they affect the overall outcome. No additional analyses were done.

Results

In total 23 articles were included in this study including twelve studies regarding PET/CT and eleven studies regarding nano-MRI. Study characteristics are shown in Table 3. All 23 articles were critically appraised according to the QUADAS guidelines (Table 2). The quality of most of the articles was high enough to be included in the report. However six articles scored high at risk of bias, which we stated as two or more insufficient categories. Because of this high risk, the results of these articles cannot be trustworthy. These six articles included Cetina et al.[20], Halpenny et al.[10], Nogami et al.[14], Birkhauser et al.[21], Hong et al.[22], and Keller et al.[23].

The overall sensitivity and specificity of PET/CT including all the studies, even the studies which scored high at risk of bias, were 56% (95% CI: 50%-63%) and 60% (95% CI: 56%-64%), respectively (Figure 2a). The overall sensitivity and specificity for nano-MRI including all of the studies were 83% (95% CI: 78%-87%) and 87% (95% CI: 84%-89%), respectively (Figure 2b).

The overall sensitivity and specificity of PET/CT excluding the articles scoring high at risk of bias according to the critical appraisal were 60% (95% CI: 53%-66%) and 53% (95% CI: 49%-58%), respectively. The overall sensitivity and specificity of nano-MRI excluding the articles scoring high at risk of bias were 84% (95% CI: 80%-88%) and 86% (95% CI: 83%-89%), respectively.

The studies regarding nano-MRI and cervical cancer were Hong et al., Keller et al., and Rockall et al. After taking only these studies into account we found an overall sensitivity and specificity of 75% (95% CI: 51%-91%) and 88% (95% CI: 75%-95%), respectively.

Discussion

The purpose of this study was to compare nano-MRI with the current technique PET/CT to find a more accurate way to diagnose lymph node metastases, since the presence of lymph node metastases can radically modify the prognoses in cervical cancer [16]. Finding the metastases is important to prescribe the right treatment for the patient. A more sensitive and specific technique will track metastases at an earlier stage and so will improve the prognoses.

The current technique PET/CT has a sensitivity and specificity of 56% (95% CI: 50%-63%) and 60% (95% CI: 56% - 64%) respectively, which is not accurate enough. Therefore a better technique is needed to diagnose lymphatic metastases. Promising is the introduction of the new method nano-MRI which uses a contrast agent, ferumoxtran-10. Because of the more accurate approach of this method smaller lymph node metastases will be detected. The iron-oxide particles are transported from the interstitial space to lymphatic vessels via macrophages. Iron loaded macrophages are not present in tumorous tissue and therefore lymphatic metastases will light up on a MR image.

To our knowledge, we are one of the first studies to compare the efficacy of PET/CT and nano-MRI in lymph node metastases in women with cervix carcinoma. In our study we found very promising results for the nano-MRI, to be precise a sensitivity of 83% (95% CI: 0.78-0.87) and a specificity of 87% (95% CI: 0.84-0.89).

However, these promising results, some limitations are present. Firstly, both the selection of the items as the critical appraisal of the articles is done by just one person, due to time constraints. This could have led to selection bias. Selection bias may also arise because we only included

Table 2: *Critical appraisal according to QUADAS guidelines. Risk of bias is judged as "low", "high", or "unclear", shown as +, – and ?, respectively. Concerns regarding applicability are rated as "low", "high" or "unclear", shown as +, – and ?, respectively.*

References				PET/CT scan					
Authors	**Year**	**No. of patients**	**Region**	**TP**	**FP**	**FN**	**TN**	**Sensitivity (%)**	**Specificity (%)**
Cetina et al. [20]	2011	16	Cervical	12	2	0	2	100	50
Choi et al. [7]	2006	22	Cervical	7	1	6	8	57,6	92,6
Chung et al. [8]	2009	34	Cervical	7	1	10	16	41,2	94,1
Goyal et al. [9]	2010	80	Cervical	14	4	10	52	58,3	92,8
Halpenny et al. [10]	2015	47	Cervical	0	0	2	45	0	100
Kim et al. [11]	2009	79	Cervical	14	14	16	35	44,1	93,9
Leblanc et al. [6]	2011	125	Cervical	7	6	14	98	33,3	94,2
Loft et al. [12]	2007	27	Cervical	3	1	1	22	75	96
Moller et al. [13]	2012	136	Cervical	38	30	18	49	57,6	71
Nogami et al. [14]	2015	70	Cervical	5	4	10	51	33,3	92,7
Signorelli et al. [15]	2011	159	Cervical	8	127	20	4	32,1	96,9
Suzuki et al. [24]	2010	100	Cervical	27	67	3	3	90	97
				Nano-MRI					
Anzai et al. [25]	2003	147	All body	99	35	18	68	85	66
Birkhauser et al. [21]	2013	75	Bladder/Prostate	14	3	6	52	70	94
Harisinghani et al. [26]	2003	80	Pelvis	33	2	0	45	100	95,7
Heesakkers at al. [17]	2008	375	Prostate	50	25	11	291	82	93
Hong et al. [22]	2012	28	Cervical	4	1	1	22	80	95,7
Keller et al. [23]	2004	13	Pelvis	1	1	3	4	25	80
Pandharipande et al. [27]	2009	230	All body regions	28	5	0	9	100	64
Rockall et al. [28]	2005	44	Endometrial/Cervical	10	4	1	27	91	87
Thoeny et al. [30]	2009	20	Bladder/Prostate	4	2	1	13	80	87
Thoeny et al. [29]	2014	120	Pelvis	24	12	9	75	72,7	86,2
Triantafyllou et al. [31]	2013	75	Bladder/Prostate	12	9	8	46	58.3	83

Table 3: *Study characteristics of the selected articles. For each article true positives (TP), false positives (FP), false negatives (FN), true negatives (TN) and sensitivity and specificity were extracted and/or calculated. Also the region of the lymphatic metastasis, which were tested, were registered.*

Study	Risk of bias				Applicability concerns		
	Patient Selection	**Index Test**	**Reference Standard**	**Flow and Timing**	**Patient Selection**	**Index Test**	**Reference Standard**
Anzai et al. [25]	+	+	–	+	+	+	–
Birkhauser et al. [21]	–	+	–	+	+	+	+
Cetina et al. [20]	–	+	?	–	–	+	?
Choi et al. [7]	+	+	+	+	+	+	+
Chung et al. [8]	+	+	+	+	+	+	+
Goyal et al. [9]	+	+	?	+	+	+	+
Halpenny et al. [10]	–	–	+	–	–	+	+
Harisinghani et al. [26]	+	+	+	+	+	+	+
Heesakkers et al. [17]	+	+	–	+	+	+	+
Hong et al. [22]	+	+	?	–	+	+	+
Keller et al. [23]	+	+	–	–	–	+	+
Kim et al. [11]	+	+	–	+	+	+	+
Leblanc et al. [6]	+	–	–	+	+	+	+
Loft et al. [12]	+	+	–	–	+	+	–
Møller et al. [13]	+	+	+	+	+	+	+
Nogami et al. [14]	+	–	?	?	+	+	+
Pandharipande et al. [27]	+	+	+	+	+	+	–
Rockall et al. [28]	+	+	+	?	+	+	+
Signorelli et al. [15]	+	?	+	?	+	+	+
Suzuki et al. [24]	+	+	?	?	+	+	+
Thoeny et al. [30]	+	+	+	+	+	–	+
Thoeny et al. [29]	+	+	+	?	+	+	+
Triantafyllou et al. [31]	+	+	+	+	+	+	+

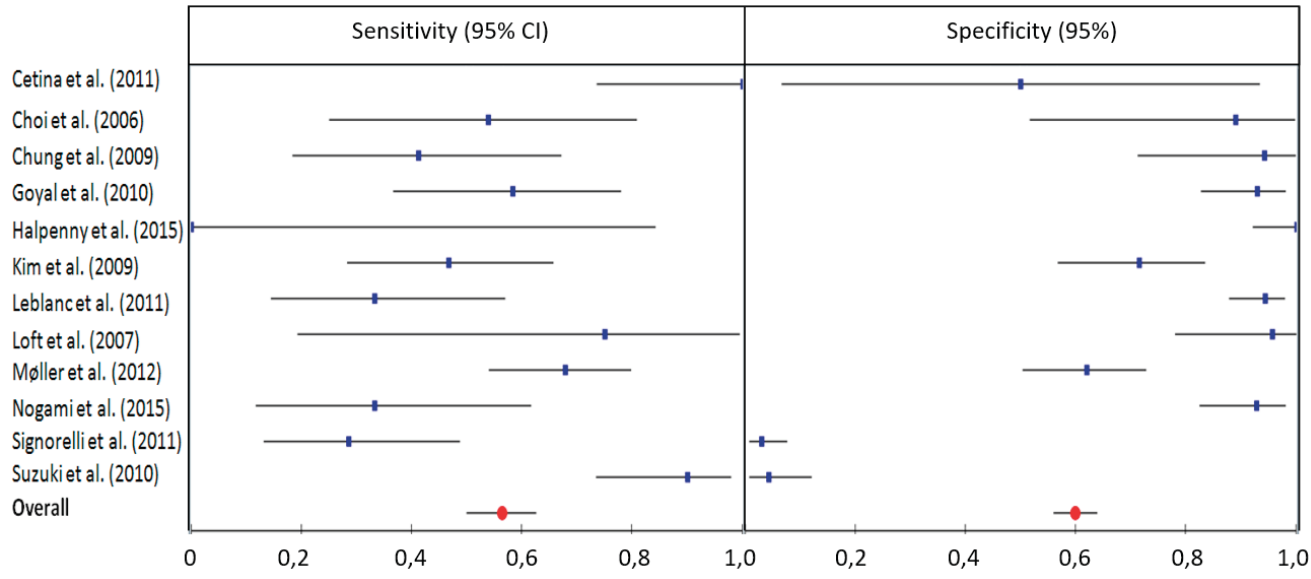

Figure 2a: *Forest plot of studies regarding PET/CT [6-15, 20, 24]. All studies included: Sensitivity = 56% (95% CI: 50%-63%); Specificity = 60% (95% CI: 56%-64%). Cetina et al., Halpenny et al., Nogami et al. excluded: Sensitivity = 60% (95% CI: 53%-66%); Specificity = 53% (95% CI: 49% - 58%).*

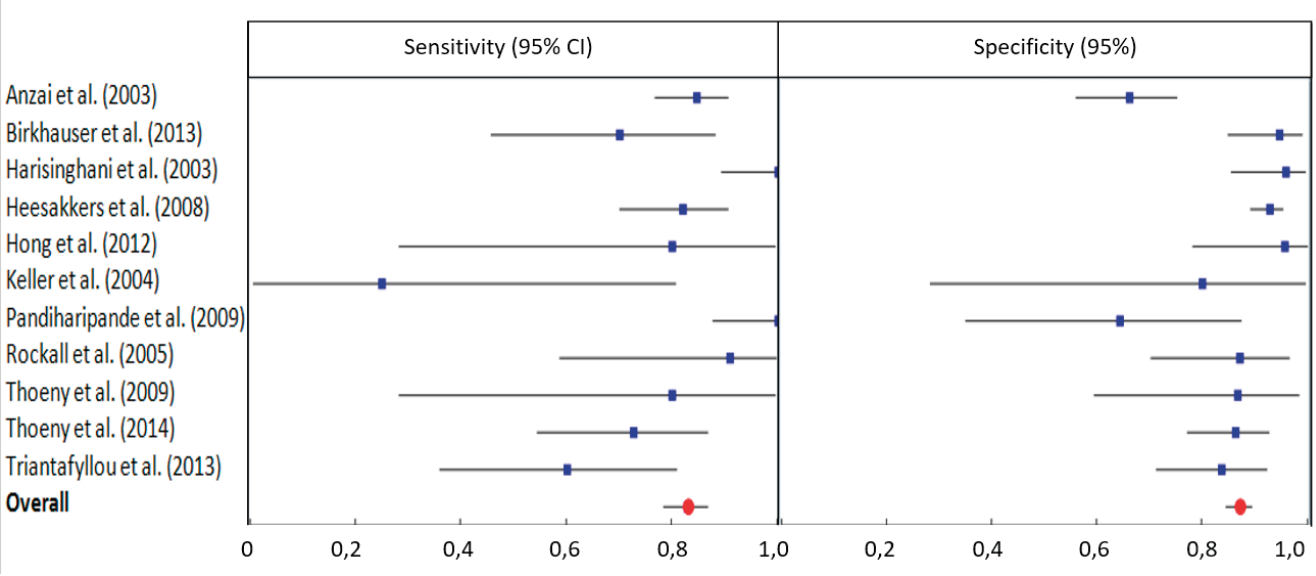

Figure 2b: *Forest plot of studies regarding nano-MRI [17, 21-23, 25-31]. All studies included: Sensitivity = 83% (95% CI: 78%-87%); Specificity = 87% (95% CI: 84%-89%). Birkhauser et al, Hong et al., Keller et al. excluded: Sensitivity = 84% (95% CI: 80%-88%); Specificity = 86% (95% CI: 83%-89%).*

articles in Dutch or English. Secondly, the studies viewing nano-MRI were not only linked to cervical cancer, but also to bladder cancer and prostate cancer. This because of the lack of researches that consider nano-MRI combined with cervical cancer. This could have had an effect on the extent to which our outcome can be generalized.

The difference in overall sensitivity and specificity of PET/CT after including all studies or excluding the articles with a high risk of bias were negligible. This also applies to the difference in overall sensitivity and specificity of nano-MRI. So per definition, excluded articles do not necessarily represent the articles with the most extreme outcomes.

The studies regarding nano-MRI and cervical cancer included two articles with a low quality and therefore the overall outcome of this analysis was not trustworthy.

A further issue is that all studies have been combined into one overall study because with our dataset it was not possible to calculate a pooled estimator in RevMan. Not every study is equally good and heterogeneity was not considered. Besides, each study is weighted equally because the population size no longer counts. We tried to solve this problem in a statistical program called SAS but we were not capable to do this in our timeframe.

A final point of discussion that occurred in some studies was the differences in use of readers. A reader is someone who assesses the outcome of the nano-MRI scan. If possible we calculated the mean outcome of the readers but if not we decided to go for the safest option and take the outcome of the worst reader. This could lead to an overestimation as well as an underestimation of the final result.

Conclusion

The sensitivity and specificity of nano-MRI are considerably more accurate than the sensitivity and specificity of PET/CT. However this research shows no hard evidence for this and more research is needed to make a solid conclusion.

It is expected that nano-MRI could be a better alternative to detect metastases in pelvic lymph nodes in women with cervical cancer.

Acknowledgments

Casper Tax* has given his consent for publication.

*Casper Tax, PhD Candidate Evidence Based Surgery, Radboudumc.

References

1. Wiebe E, Denny L, Thomas G: Cancer of the cervix uteri. Int J Gynaecol Obstet 2012, 119 Suppl 2:S100-109.
2. Burd EM: Human Papillomavirus and Cervical Cancer. Clinical Microbiology Reviews 2003, 16(1):1-17.
3. Obstetrics IFOGa: FIGO staging of gynecologic cancers. International journal of gynecological cancer : official journal of the International Gynecological Cancer Society 1995, 5:319-324.
4. Pecorelli S: Revised FIGO staging for carcinoma of the vulva, cervix, and endometrium. International journal of gynaecology and obstetrics: the official organ of the International Federation of Gynaecology and Obstetrics 2009, 105(2):103-104.
5. Tax C, Rovers MM, de Graaf C, Zusterzeel PL, Bekkers RL: The sentinel node procedure in early stage cervical cancer, taking the next step; a diagnostic review. Gynecologic oncology 2015, 139(3):559-567.
6. Leblanc E, Gauthier H, Querleu D, Ferron G, Zerdoud S, Morice P, Uzan C, Lumbroso S, Lecuru F, Bats AS et al: Accuracy of 18-Fluoro-2-deoxy-d-glucose positron emission tomography in the pretherapeutic detection of occult para-aortic node involvement in patients with a locally advanced cervical carcinoma. Annals of surgical oncology 2011, 18(8):2302-2309.
7. Choi HJ, Roh JW, Seo SS, Lee S, Kim JY, Kim SK, Kang KW, Lee JS, Jeong JY, Park SY: Comparison of the accuracy of magnetic resonance imaging and positron emission tomography/computed tomography in the presurgical detection of lymph node metastases in patients with uterine cervical carcinoma: A prospective study. Cancer 2006, 106(4):914-922.
8. Chung HH, Park NH, Kim JW, Song YS, Chung JK, Kang SB: Role of integrated PET-CT in pelvic lymph node staging of cervical cancer before radical hysterectomy. Obstetrical and Gynecological Survey 2009, 64(4):237-238.
9. Goyal BK, Singh H, Kapur K, Duggal BS, Jacob MJ: Value of PET-CT in avoiding multimodality therapy in operable cervical cancer. International journal of gynecological cancer : official journal of the International Gynecological Cancer Society 2010, 20(6):1041-1045.
10. Halpenny D, Johnston C, Sheehy N, Keogan M: 18F-FDG-PET/CT is of limited value in primary staging of early stage cervical cancer. Abdominal imaging 2015, 40(1):127-133.
11. Kim SK, Choi HJ, Park SY, Lee HY, Seo SS, Yoo CW, Jung DC, Kang S, Cho KS: Additional value of MR/PET fusion compared with PET/CT in the detection of lymph node metastases in cervical cancer patients. European Journal of Cancer 2009, 45(12):2103-2109.
12. Loft A, Berthelsen AK, Roed H, Ottosen C, Lundvall L, Knudsen J, Nedergaard L, Hojgaard L, Engelholm SA: The diagnostic value of PET/CT scanning in patients with cervical cancer: A prospective study. Gynecologic oncology 2007, 106(1):29-34.
13. Moller AK, Loft A, Berthelsen AK, Pedersen KD, Graff J, Christensen CB, Costa JC, Skovgaard LT, Perell K, Petersen BL et al: A prospective comparison of 18F-FDG PET/CT and CT as diagnostic tools to identify the primary tumor site in patients with extracervical carcinoma of unknown primary site. The oncologist 2012, 17(9):1146-1154.
14. Nogami Y, Banno K, Irie H, Iida M, Kisu I, Masugi Y, Tanaka K, Tominaga E, Okuda S, Murakami K et al: The efficacy of preoperative positron emission tomography-computed tomography (PET-CT) for detection of lymph node metastasis in cervical and endometrial cancer: Clinical and pathological factors influencing it. Japanese journal of clinical oncology 2015, 45(1):26-34.
15. Signorelli M, Guerra L, Montanelli L, Crivellaro C, Buda A, Dell'Anna T, Picchio M, Milani R, Fruscio R, Messa C: Preoperative staging of cervical cancer: Is 18-FDG-PET/CT really effective in patients with early stage disease? Gynecologic oncology 2011, 123(2):236-240.
16. Devilee L.A.C. HLC, Lankhof J., Orriens L.B., van Velthoven A.S.M.: The prognostic value of lymphatic metastasis in cervical cancer: effect on five year survival. 2016.
17. Heesakkers RA, Hovels AM, Jager GJ, van den Bosch HC, Witjes JA, Raat HP, Severens JL, Adang EM, van der Kaa CH, Futterer JJ et al: MRI with a lymph-node-specific contrast agent as an alternative to CT scan and lymph-node dissection in patients with prostate cancer: a prospective multicohort study. The Lancet Oncology 2008, 9(9):850-856.
18. Radboudumc, Veel gestelde vragen over MRI Nano, 2016 [https://www.radboudumc.nl/Zorg/Onderzoeken/Pages/VeelgesteldevragenoverMRINano.aspx]
19. Whiting PF, Rutjes AW, Westwood ME, Mallett S, Deeks JJ, Reitsma JB, Leeflang MM, Sterne JA, Bossuyt PM: QUADAS-2: a revised tool for the quality assessment of diagnostic accuracy studies. Ann Intern Med 2011, 155(8):529-536.
20. Cetina L, Serrano A, Cantu-de-Leon D, Perez-Montiel D, Estrada E, Coronel J, Hernandez-Lucio M, Duenas-Gonzalez A: F18-FDG-PET/CT in the evaluation of patients with suspected recurrent or persistent locally advanced cervical carcinoma. Revista de investigacion clinica; organo del Hospital de Enfermedades de la Nutricion 2011, 63(3):227-235.
21. Birkhauser FD, Studer UE, Froehlich JM, Triantafyllou M, Bains LJ, Petralia G, Vermathen P, Fleischmann A, Thoeny HC: Combined ultrasmall superparamagnetic particles of iron oxide-enhanced and diffusion-weighted magnetic resonance imaging facilitates detection of metastases in normal-sized pelvic lymph nodes of patients with bladder and prostate cancer. European urology 2013, 64(6):953-960.
22. Hong Y, Xiang L, Hu Y, Zhou Z, Yu H, Zhu B: Interstitial magnetic resonance lymphography is an effective diagnostic tool for the detection of lymph node metastases in patients with cervical cancer. BMC cancer 2012, 12 (no pagination)(360).
23. Keller TM, Michel SC, Frohlich J, Fink D, Caduff R, Marincek B, Kubik-Huch RA: USPIO-enhanced MRI for preoperative staging of gynecological pelvic tumors: preliminary results. European radiology 2004, 14(6):937-944.
24. Suzuki K, Nakamoto Y, Onishi Y, Sakamoto S, Senda M, Kita M, Sugimura K: Low-dose non-enhanced CT versus full-dose contrast-enhanced CT in integrated PET/CT studies for the diagnosis of uterine cancer recurrence. European journal of nuclear medicine and molecular imaging 2010, 37(8):1490-1498.
25. Anzai Y, Piccoli CW, Outwater EK, Stanford W, Bluemke DA, Nurenberg P, Saini S, Maravilla KR, Feldman DE, Schmiedl UP et al: Evaluation of neck and body metastases to nodes with ferumoxtran 10-enhanced MR imaging: phase III safety and efficacy study. Radiology 2003, 228(3):777-788.
26. Harisinghani MG, Barentsz J, Hahn PF, Deserno WM, Tabatabaei S, Van de Kaa CH, De la Rosette J, Weissleder R: Noninvasive detection of clinically occult lymph-node metastases in prostate cancer. New England Journal of Medicine 2003, 348(25):2491-2499.
27. Pandharipande PV, Mora JT, Uppot RN, Goehler A, Braschi M, Halpern EF, Gazelle GS, Harisinghani MG: Lymphotropic nanoparticle-enhanced MRI for independent prediction of lymph node malignancy: a logistic regression model. AJR American journal of roentgenology 2009, 193(3):W230-237.
28. Rockall AG, Sohaib SA, Harisinghani MG, Babar SA, Singh N, Jeyarajah AR, Oram DH, Jacobs IJ, Shepherd JH, Reznek RH: Diagnostic performance of nanoparticle-enhanced magnetic resonance imaging in the diagnosis of

lymph node metastases in patients with endometrial and cervical cancer. Journal of clinical oncology : official journal of the American Society of Clinical Oncology 2005, 23(12):2813-2821.
29. Thoeny HC, Froehlich JM, Triantafyllou M, Huesler J, Bains LJ, Vermathen P, Fleischmann A, Studer UE: Metastases in normal-sized pelvic lymph nodes: detection with diffusion-weighted MR imaging. Radiology 2014, 273(1):125-135.
30. Thoeny HC, Triantafyllou M, Birkhaeuser FD, Froehlich JM, Tshering DW, Binser T, Fleischmann A, Vermathen P, Studer UE: Combined Ultrasmall Superparamagnetic Particles of Iron Oxide-Enhanced and Diffusion-Weighted Magnetic Resonance Imaging Reliably Detect Pelvic Lymph Node Metastases in Normal-Sized Nodes of Bladder and Prostate Cancer Patients. European urology 2009, 55(4):761-769.
31. Triantafyllou M, Studer UE, Birkhauser FD, Fleischmann A, Bains LJ, Petralia G, Christe A, Froehlich JM, Thoeny HC: Ultrasmall superparamagnetic particles of iron oxide allow for the detection of metastases in normal sized pelvic lymph nodes of patients with bladder and/or prostate cancer. European Journal of Cancer 2013, 49(3):616-624.

EXAM QUESTIONS

As RAMS aims to enlighten both students and professionals, we would like to present you two exam questions. Find out if you can remember what you learned during the bachelor! The right answers can be found further on in this journal.

We challenge you!

Question 1
After finishing a marathon, many runners immediately cease walking. It frequently happens that a participant faints behind the finish line. What is the primary cause of this? This is primarily caused by a decrease in:

A. blood pressure
B. venous return
C. cardiac output

Question 2
In case of chronic alcoholism, the VLDL concentration in the blood is:

A. decreased
B. normal
C. elevated

The answers to these questions can be found on page 15 in this journal.